

Custom Radiation Eye Shields (For Use During Electron Beam Irradiation): A Case Report

ABSTRACT: *For most Ocularists, interventions are secondary to the loss of an eye. Recently though, Ocularists have had the opportunity to assist in procedures which focus on preservation of a diseased eye. The following is a description of a collaborative effort between the Ophthalmologist and the Ocularist to achieve a positive treatment outcome.*

Michael O. Hughes

Artificial Eye Clinic
Vienna, Virginia

Robert Kling

M.D.

Ophthalmologist and Medical
Physicist
Falls Church, Virginia

THE OPHTHALMOLOGIST'S POINT OF VIEW

F.K., a 66-year-old white male office worker, stationed overseas had always been in excellent health. Regular physical examinations with adequate laboratory studies showed no abnormalities except mild diabetes controllable by diet.

In 1989 at age 62, the patient noticed a new growth beneath the bulbar conjunctive of his left eye. Excision biopsy was interpreted as small cell lymphoma. The specimen was very small. On return to the USA some suspicious looking tissue was removed from the same site, but it was only scar tissue. Twice more when suspicious looking tissue appeared, local excision revealed only fibrous tissue.

Complete hematological examination revealed no other lymphoma.

Both eyes were re-examined every six months. There were no abnormalities other than the scars of previous excisions. Vision remained excellent in each eye.

In July, 1993 at routine examination of a small mass was discovered deep in the upper fornix of both eyes. It was completely asymptomatic. Its appearance suggested lymphoma. At biopsy complete excision was not possible because the tissue extended around the insertion of the superior rectus muscles. Histologic examination and immunological studies showed that it was diffuse malignant lymphoma B cell type.

After discussion with other specialists, in tumor conference irradiation was decided upon as the best mode of treatment. He was to be irradiated en face with an electron beam 4 cm in diameter. The electrons were to be accelerated in energy of six million electron volts (mev). He was to receive 200 centigray daily for fifteen days for a total of 30 Gray.

Repeat ophthalmological examination confirmed that the patient had no cataracts and no abnormality of his lids, lashes, or lacrimal system.

Calculations indicated that the lenses would be adequately protected by a 3.3 mm layer of lead or by a 3.8 mm layer of copper. Copper is more eas-

KEY WORDS:

Irradiation, scleral cover shell,
Cornea, lens, lymphoma, conjunctiva

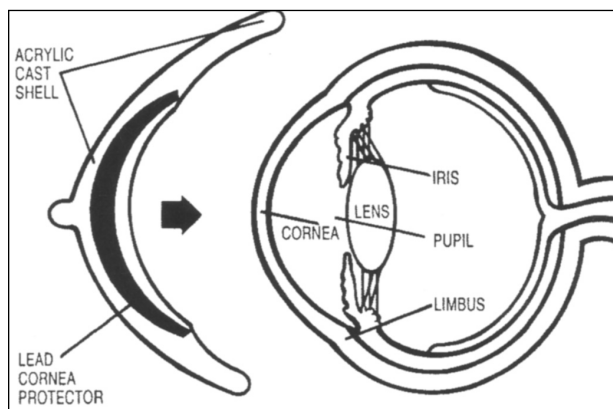


FIGURE 1 Diagram shows the Acrylic Cast Shell (complete with lead center) which will be placed over top of the patient's eye.

ily machined; lead was more readily available. The physicist at the hospital where treatment was to be performed preferred lead because he had more experience with lead shields than with copper. The Ocularist (M.H.) was asked to fashion appropriate shields which would protect the lenses while permitting adequate irradiation of the fornices.

The shields were first tested on a phantom which had a shape comparable to the patient's head. Received dose was measured at strategic locations within the phantom and isodose curves were drawn. This indicated that the dose to the fornices would be adequate while the dose to the lens would be negligible.

Treatment was carried out as planned. Side effects were almost non-existent. The shields were easily inserted and removed; and they caused no discomfort. Post irradiation examination at two weeks showed no bad side effects. At six weeks no lymphoma could be seen through the normal-looking conjunctiva. Tear production was normal as it was before treatment. More than half his lashes had fallen out, but already a few new ones were growing.

Based on past cases his prognosis for life and good health is believed to be excellent. Based on calculated dose and on phantom measurements, it is unlikely that he will develop cataracts. The actual outcome for his lenses will not be known for two or three years.

Comment: Sub-conjunctival lymphoma is a malignant condition separately identifiable from systemic lymphoma. After good local treatment the prognosis is good. The most important complications of

local irradiation are cataract and dry eye. The lacrimal gland, the accessory lacrimal glands, and the conjunctival mucus glands cannot be shielded in a case such as this one. The lens can be shielded. The usual shields are awkward, uncomfortable and inconsistent. In this case the shields were excellent.

THE OCULARIST'S POINT OF VIEW

Because the patient was going to receive numerous radiation treatments, the ophthalmologist suggested that the radiation shields be custom made. The custom made shields versus the traditional stock shield was proposed for several reasons. First, stock shields often times do not provide an appropriate fit, and floating and movement can occur. This can be a critical problem during radiation treatments, and endanger the lens of the eye. Second, the cornea can be scratched because of an ill-fitted shield.

Custom lead eye shields are impression fitted, and designed to fit the globe more accurately than stock shields. The custom shield is contoured to the patient's globe, and protects the patient's lens (of his natural eye) from unexpected motion during radiation treatments. The lead is encased in clear (smoothly polished) acrylic, causing minimal irritation to the cornea.

The initial fabrication process involved impressions of both globes. Working with the Ophthalmologist, a drop of Tetracaine Hydrochloride Ophthalmic Solution (USP, 0.5%) was used to ease the discomfort of the alginate.

Once impressions were completed, stone molds were poured, and clear acrylic trial shells were cast. The




FIGURE 2 Patient wearing Custom Radiation Eye Shields.

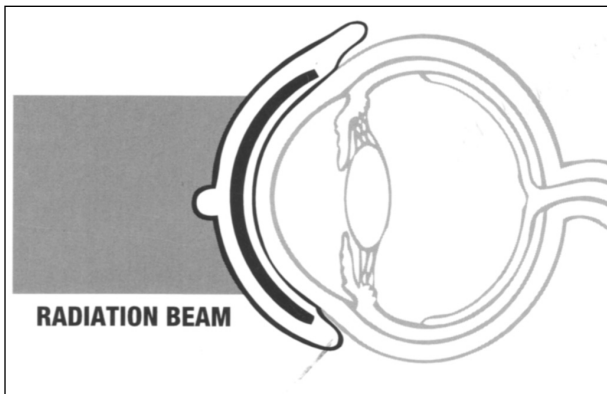


FIGURE 3 Illustration showing concept of Radiation Shields; which fits snugly over the patients eye, protecting the lenses while permitting adequate irradiation of the fornicies.

trial shells showed an approximate fit, and enabled the positioning of the lead, which would be imbedded into the finished shell. The clear trial shells also show how well the shield would 'track' during unwanted motion.

To position the lead, sticky wax was used to adhere an iris fitting stem directly over the pupil. The lead button, which is 12.5mm in diameter, was then cast into a mold of the trial shell/attached peg. The 12.5mm lead button needed to be positioned **DIRECTELY OVER** the pupil to protect the 10.7mm lens of the patient's eye. (As with the trial shell, clear acrylic was used to encase the lead)

In making the Lead Button, a wax cast of the desired shape was formed to the desired size and shape. The wax shape was invested into a two piece, gypsum-bound investment material capable of withstanding the high temperature of molten lead.

A propane torch was used to melt the lead. The molten lead was then poured in to the mold (through an attached sprue). Once cooled, the lead was finished (which was relatively easy since lead is very pliable) and inserted in the mold and cast in the above stated procedure.

A small 'nub' was placed directly over the anterior surface allowing easy insertion and removal (with the fingers or instruments) by the Ophthalmologist or Radiologist.

CONCLUSION

This case allowed these professionals to utilize their respective skills and techniques to fabricate an effec-

tive device that prevented a probable loss in this patient's life. This case shares new dimensions to practice patterns, and adds a new element to the type of care available to patients.

CORRESPONDENCE TO:

Michael O. Hughes
Artificial Eye Clinic of Washington
307 Maple Avenue West
Suite B
Vienna, VA 22180-5607

email: eye226@aol.com
www.artificialeyeclinic.com

Special note: The phantom studies and the irradiation were performed by the staff of The Cancer Center at Fairfax Hospital, Fairfax, Virginia